



DIAGNOSTIC CHALLENGE

Check the correct answer on page 72

Case 1

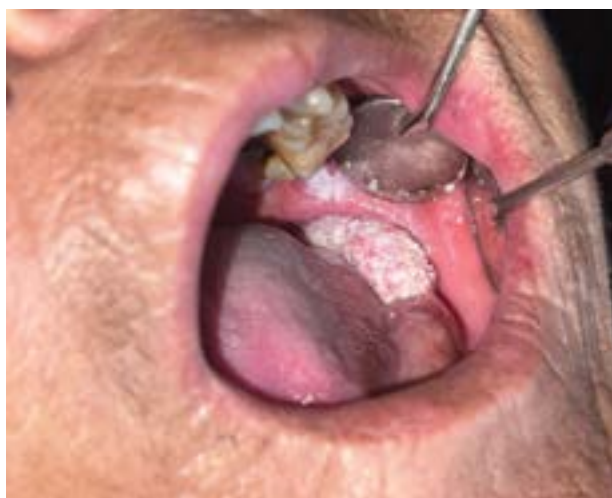

Figure 1

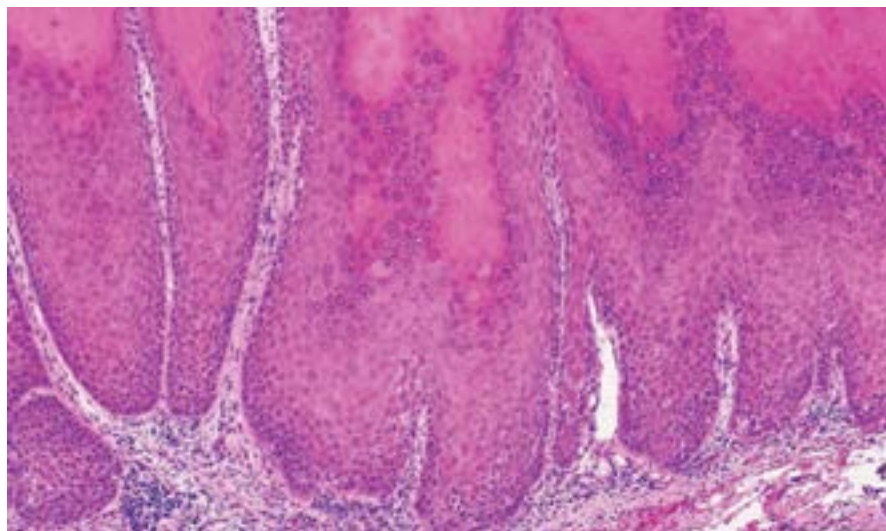


Figure 2

A 72-year-old female presents with gradually enlarging, warty overgrowth on the left buccal mucosa, noted over the past 06 months. She has a history of wearing ill-fitting dentures for 8 years, causing chronic irritation at the site. Examination reveals exophytic, whitish lesions with no ulceration, and no palpable lymphadenopathy (Figure 1). Histopathology is shown in Figure 2.

1. What is the differential diagnosis of the case based on clinical findings?
2. Looking at histopathology what is your definite diagnosis?

DIAGNOSTIC CHALLENGE

Check the correct answer on page 72

Case 2

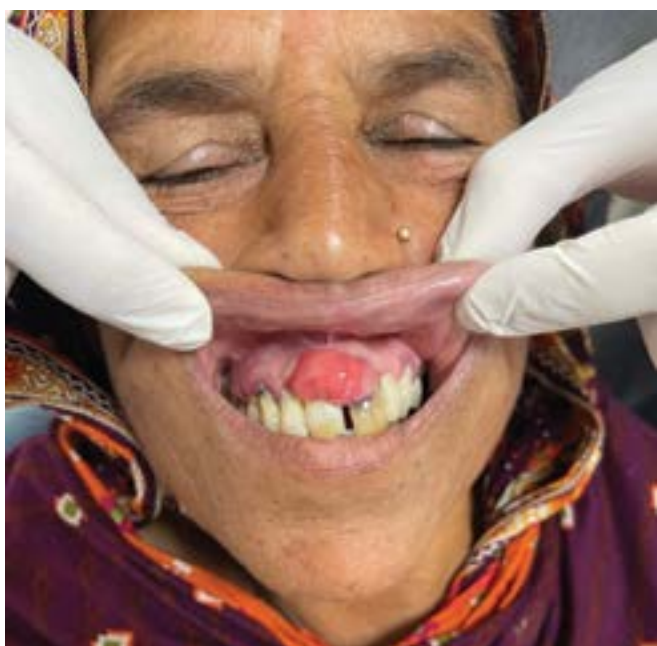

Figure 1

A 52 year old female patient presented with red, swollen growth on my upper gum that bleeds occasionally. The lesion appeared approximately 2-3 months ago and has gradually increased in size. There was mild discomfort but no significant pain. History of the patient revealed poor oral hygiene practices with no associated systemic symptoms. Clinical examination reveals a red, smooth, lobulated growth on the labial gingiva of the maxillary anterior region. The lesion is well-defined, highly vascular with surrounding gingiva showing mild inflammation due to poor oral hygiene (Figure 1). No lymphadenopathy or signs of infiltration were noted.

1. What is the diagnosis of patient?
2. What diagnostic tests are required to confirm the diagnosis?